Utilização de sensor não invasivo para avaliação da complacência intracraniana no pós-operatório tardio de hipertensão intracraniana idiopática: relato de caso

Artigo Original

Luiz Gabriel Gonçalves Cherain[1], Mateus Gonçalves de Sena Barbosa[1], Rafaela Luiza Vilela de Souza[1], Rafaela de Souza e Paula[1], Geovana Ribeiro Campos[1], Isadora Silva[1], Elaine Peixoto[1], Nicollas Nunes Rabelo[2], M.D., Ph.D

1 Atenas Medical School, Passos-MG, Brazil

2 Brain4Care, São Paulo-SP, Brazil

E-mail para contato: lgcherain@gmail.com

Resumo

O objetivo deste estudo é relatar o uso de um sensor não invasivo para avaliação da complacência intracraniana (CIC) em pacientes com queixa de enxaqueca. Este relato de caso apresenta uma paciente de 34 anos, do sexo feminino, que foi submetida ao tratamento de hipertensão intracraniana idiopática (HII) com a colocação de uma derivação lombo-peritoneal não ajustável. Após um ano, ela apresentou cefaleia e sinais de hiperdrenagem liquórica. Foi realizado um monitoramento não invasivo da CIC, sugerindo uma redução da complacência, mas sem alteração na pressão de abertura da válvula. Assim, foi feito o diagnóstico de enxaqueca, com melhora após o monitoramento cerebral, levando à resolução do quadro sem nenhuma nova intervenção cirúrgica. Com esse caso, concluímos que o uso do sensor não invasivo ajudou a equipe médica a compreender as informações obtidas pela curva da CIC no consultório e no manejo de pacientes com queixas de cefaleia, apoiando a tomada de decisões clínicas, melhorando a qualidade do atendimento, correlacionando com doenças subjacentes e com a segurança do paciente.

Abstract

This study aims to report the use of a noninvasive sensor to assess intracranial compliance (ICC) in patients complaining of migraine. This case report presents a 34-year-old, female patient that was treated for idiopathic intracranial hypertension (IIH) by placing a non-adjustable lumboperitoneal shunt. After one year, she presented with headache and signs of overdrainage. Noninvasive monitoring of ICC was done, suggesting a reduction in the ICC, but no change in the opening pressure of the valve. A diagnosis of migraine was made, with improvement after brain monitoring, leading treatment without any new surgical intervention. With this case, we conclude that the use of noninvasive sensor helped the medical team to understand the information obtained by the ICP curve in the office, and in the management of patients with headache complaints, supporting clinical decision making, improving the quality of care, correlated with underlying diseases, and patient safety.

INTRODUCTION

Migraine is a disabling, multifactorial, hereditary disease caused by increased excitability of the central nervous system. Its origin is associated with a neurological disorder in multiple brain areas. Seizures last from a few hours to three days and usually begin with prodromes and aura transient focal neurological symptoms. The pain begins with the activation of meningeal nociceptors at the origin of the trigeminovascular system, responsible for transmitting this sympathetic and parasympathetic information to the brain. It can be initiated and aggravated by routine activities, such as irregular sleep and eating, stress, hormonal changes, alcohol intake, noises, lights, and aromas, which makes it incapacitating and decreases the patient's quality of life 3, 6, 7, 8, 10.

In this report, we present a patient who benefited from noninvasive intracranial pressure (ICP) monitoring in the management of migraine in the late postoperative period of idiopathic intracranial hypertension (IIH).

CASE STUDY

A 34-year-old female patient, obese, in use of oral contraceptive was treated for IIH by placing a non-adjustable lumboperitoneal shunt with opening pressure of 60 cm H2O. After one year, she presented with headache and signs of overdrainage seen by magnetic resonance imaging (MRI) with contrast enhancement in the meninges. Probably, the system destabilized because the patient lost weight. After 6 months she stabilized and become asymptomatic. Two years after the surgery, she presented with typical migraine symptoms and a noninvasive intracranial compliance (ICC) monitoring was performed with Brain 4 Care noninvasive sensor to assess intracranial compliance in the management of migraine. This noninvasive examen showed a curve with an altered ICC and a P2/P1 ratio of 1.21, suggesting a reduction in the ICC (figure 1). Although, there was no change in the opening pressure, the MRI maintained the same previous findings and the hemodynamic control remained stable.

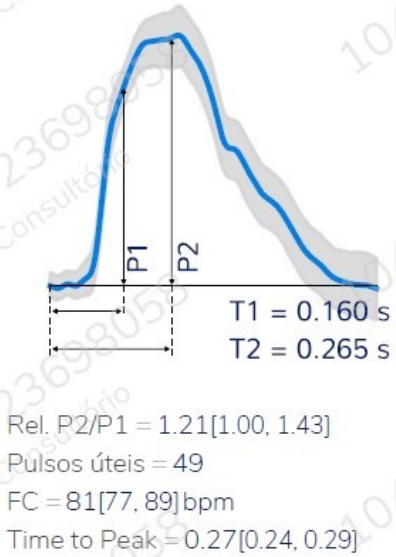

Figure 1. The altered ICP compliance curve in the first monitoring suggests an ICC reduction and represents a migraine headache.

Given the clinical context, she was treated with topiramate and propranolol for migraine symptoms. Additionally, ibuprofen, and dipyrone were used.

After one month drug treatment, with the clinical context of post IIH, a new ICP pulse monitoring was performed (figure 2), whose value was 1.36, however, this was justified by menstrual headache-pain. Therefore, the contraceptive was changed from oral contraceptive to an intrauterine device (IUD), and the prescribed medication was maintained.

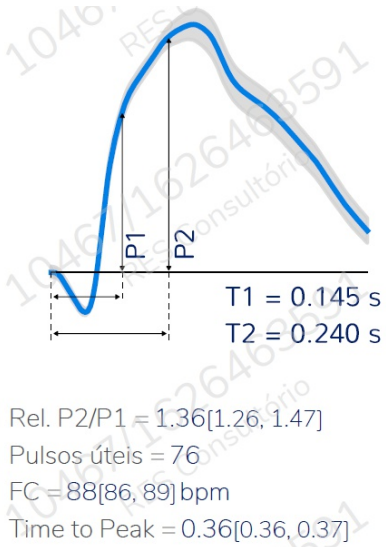

Figure 2. The second ICP monitoring. In this moment, the patient was in the menstrual period and with menstrual pain.

After 3 months, the patient presented total improvement of the compliance and the migraine after the treatment (figure 3).

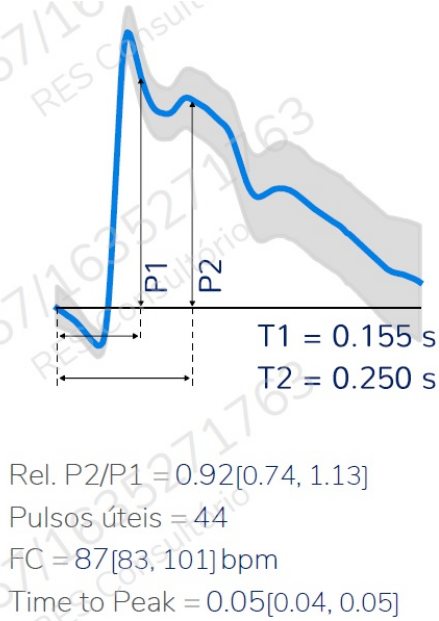

Figure 3. The ICP curve 3 months after the treatment showed a normal P2/P1 ratio (under 1.0), indicating recover of the patient symptoms

DISCUSSION

Several diseases were considered and carefully eliminated to correctly diagnose the patient in question. Initially, the possibility of migraine-type headache (migraine) secondary to the recurrence of the IIH, was

considered.

The noninvasive method of ICP assessment and compliance analysis, using the Brain4Care (B4C) device, was used for patient follow-up. To understand the results, it is necessary to know that the monitoring of ICP happens through the evaluation of the waves originated in each cardiac cycle, in which the blood flow is directed to the brain. Therefore, 3 waves are formed: P1 (percussion wave, which reflects the arterial pressure transmitted from the choroid plexus to the cerebral ventricle), P2 (tidal wave, related to intracranial compliance), P3 (dichroitic wave, related to the aortic valve closure during diastole), and for validation of a good result, the waves should remain P1>P2>P3.

Noninvasive monitoring of ICC in the office was performed and made it possible to exclude the hypothesis of intracranial hypertension (ICH) due to an IIH, since a mean P2/P1 ratio of 1.21 was verified, that is, the P2 component was higher than P1, suggesting reduced ICC, however, without alteration in the opening pressure of the cerebrospinal fluid (CSF). In the posterior consultation, without overweight, the patient referred a new episode of migraine, reporting being in her menstrual period accompanied by menstrual pain, and the noninvasive monitoring indicated a P2/P1 ratio of 1.36. The clinical view of the patient, her history of obesity and use of oral contraceptives associated with the identification of decreased brain compliance without pressure change, by means of noninvasive monitoring, were determinant in the diagnosis of migraine, a multifactorial disease that has a strong hormonal influence 1, 2, 4, 5, 9, 11.

Especially this case, the noninvasive monitoring was fundamental because, she had hydrodynamic disease, and the decision-making is really tough, when headache really appear after months of the treatment. In this case was possible to know exactly what was happen and compare the treatments.

This study aims to show that diagnosis and treatment, as well as the evaluation of the ICP and ICC, can be made easier with the use of noninvasive monitoring in the doctor's office, avoiding hospital admissions and invasive procedures.

CONCLUSION

With this case, we conclude that the use of noninvasive sensor helped the medical team to understand the information obtained by the ICP curve in the office, and in the management of patients with headache complaints, supporting clinical decision making, improving the quality of care, correlated with underlying diseases and procedural and patient safety.

REFERENCES

1. Aegidius K, Zwart J-A, Hagen K, Schei B, Stovner LJ. Oral contraceptives and increased headache prevalence: the Head-HUNT Study. Neurology. 2006 Feb 14;66(3):349–53.

2. Brandes JL. The influence of estrogen on migraine: a systematic review. JAMA. 2006 Apr 19;295(15):1824–30.

3. Burstein R, Noseda R, Borsook D. Migraine: multiple processes, complex pathophysiology. J Neurosci. 2015 Apr 29;35(17):6619-29. doi: 10.1523/JNEUROSCI.0373-15.2015. PMID: 25926442; PMCID: PMC4412887.

4. Faubion SS, Batur P, Calhoun AH. Migraine Throughout the Female Reproductive Life Cycle. Mayo Clin Proc. 2018 May;93(5):639–45.

5. Granella F, Sances G, Pucci E, Nappi RE, Ghiotto N, Napp G. Migraine with aura and reproductive life events: a case control study. Cephalalgia. 2000 Oct;20(8):701–7.

6. Joubert J. Enxaqueca- diagnóstico e tratamento. Aust Fam Doctor. 2005 Ago;34(8):627-32. 16113698.

7. Mallery RM, Friedman DI, Liu GT. Headache and the pseudotumor cerebri syndrome. Curr Pain Headache Rep. 2014 Sep;18(9):446. doi: 10.1007/s11916-014-0446-z. PMID: 25086688.

8. PORTO, C. C. Semiologia Médica. 8. ed. Rio de Janeiro: Guanabara Koogan, 2019

9. Sacco S, Ricci S, Degan D, Carolei A. Migraine in women: the role of hormones and their impact on vascular diseases. J Headache Pain. 2012 Apr;13(3):177–89.

10. Silberstein SD. Migraine. Lancet. 2004 Jan 31;363(9406):381-91. doi: 10.1016/S0140-6736(04)15440-8. PMID: 15070571.

11. Wöber C, Brannath W, Schmidt K, Kapitan M, Rudel E, Wessely P, et al. Prospective analysis of factors related to migraine attacks: the PAMINA study. Cephalalgia. 2007 Apr;27(4):304–14.